

Positive predictive values of non-thyroid head & neck cytopathology specimens at Shrewsbury and Telford Hospitals NHS Trust (SaTH)

Authors: C Hayes, K Harrison, D Ole, M Ruwaisdeen

Introduction

Cytopathology is a cheap, quick tool to provide a diagnosis or guide management in head & neck lesions.

It is quicker and less invasive than biopsy, with few postprocedural complications.

At SaTH cytology is coded according to its morphology on a 5-point scale. This is primarily for audit purposes, and it does not appear on our reporting, though in practice it also acts as a guidance for pathologists in their own practice and in their communication. Knowing the positive predictive values for these codes should translate into the confidence clinicians have in our diagnosis.

The internal coding system at SaTH

CODE	EXPANSION
NGC1	Unsatisfactory
NGC2	No malignant cells seen
NGC3	Atypia (mild)
NGC4	Atypia (suspicious)
NGC5	Malignant

Methodology

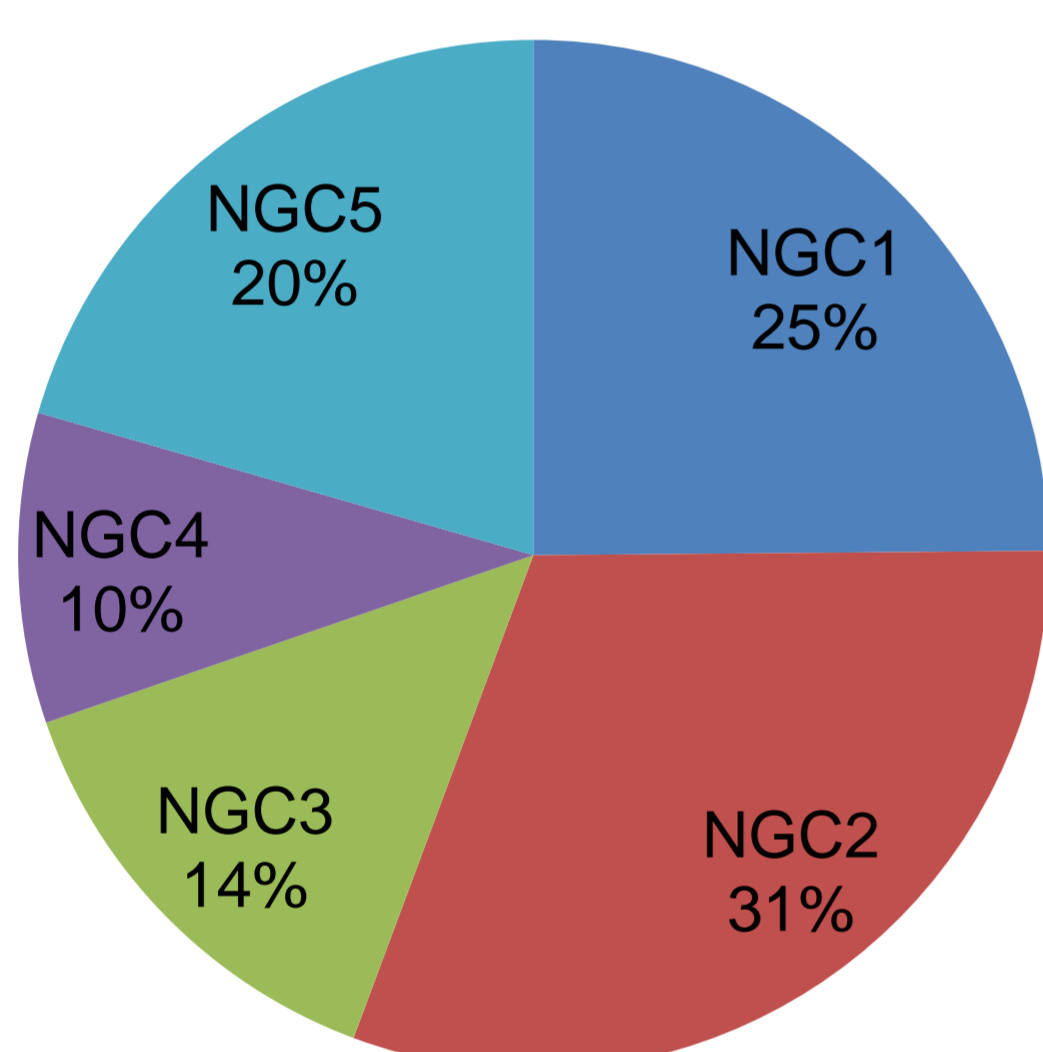
- Cases taken from the local reporting system between 1/1/18 and 31/9/18.
- 201 cases identified. 77 were from the salivary gland, 128 were 'neck lumps.'
- Cytology and subsequent histology/clinic letters reviewed.
- Identified as either 'benign' or 'malignant' on final outcome.
- PPV for malignancy then calculated for each NGC category as above.

Standards/Criteria

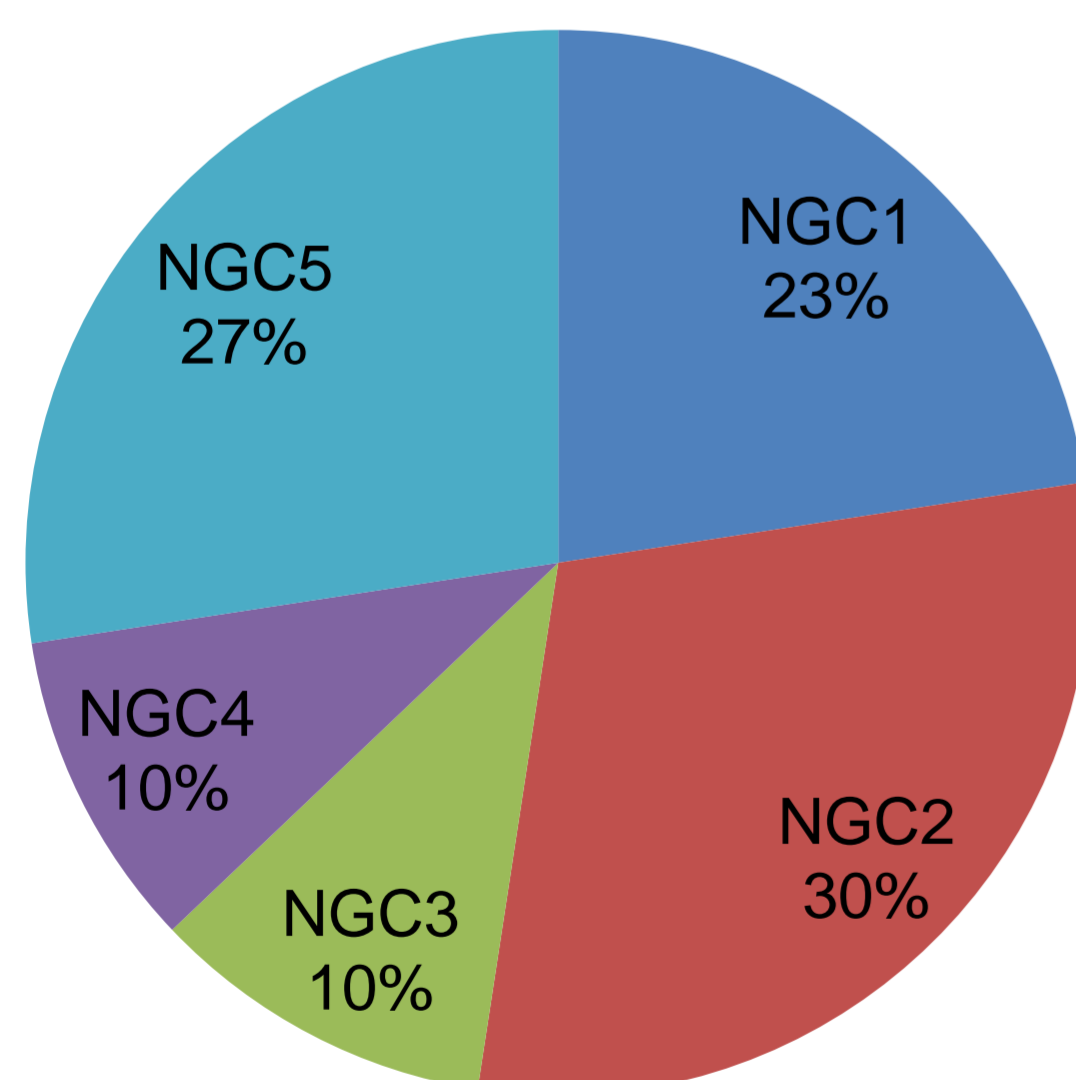
- No current published standards from any national bodies (e.g. NICE or RCPATH) regarding expected PPV values
- Ranges from 83% to 99% have been quoted for all specimens.¹⁻⁴
- The following standards (and criteria) are departmental, extrapolated from a local audit on thyroid FNA specimens:

1. All cases should be coded correctly (100%)
2. PPV for NGC5 (100%)
3. PPV for NGC4 (>90%)
4. PPV for NGC2 (<5%)

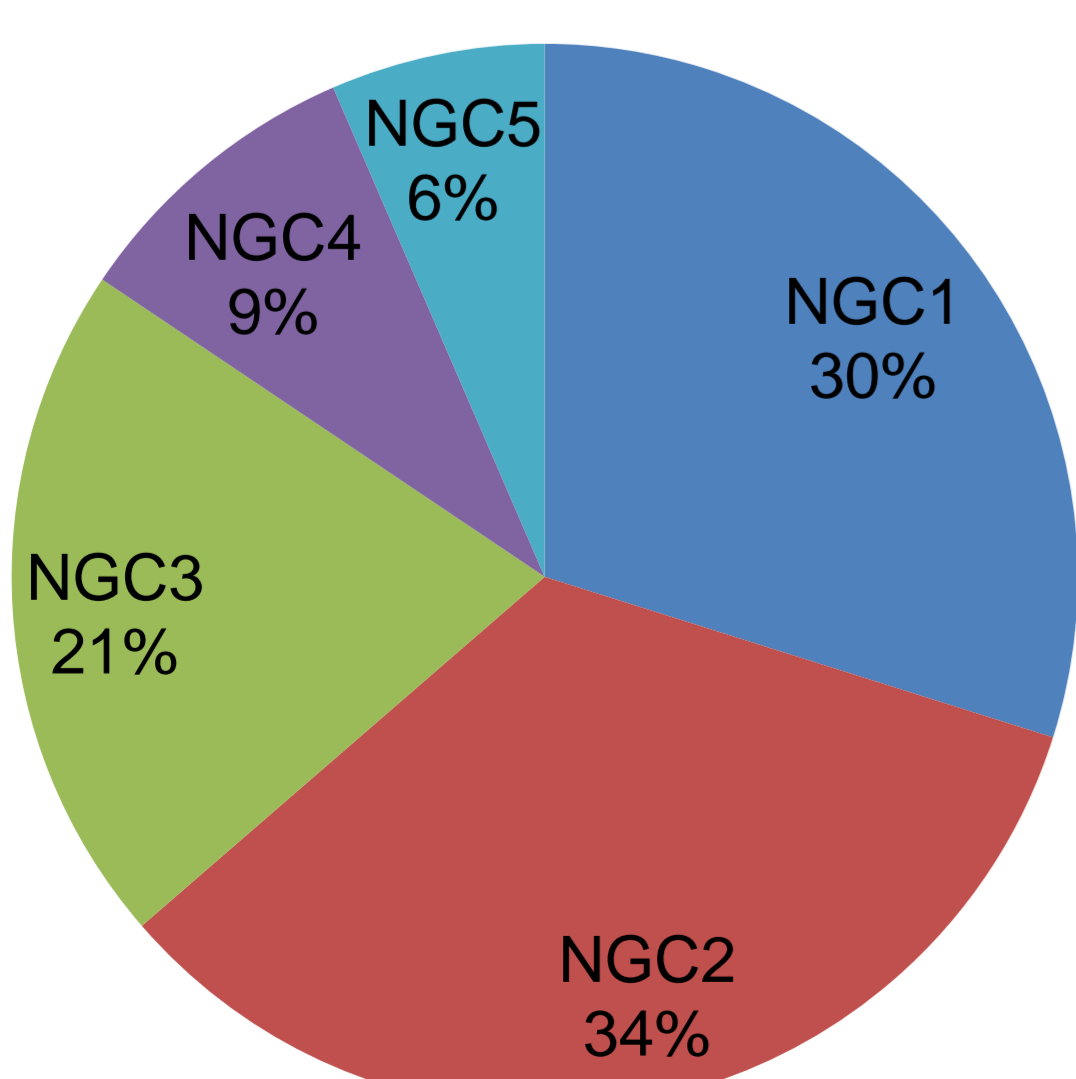
The spread of cases from NGC1 to 5



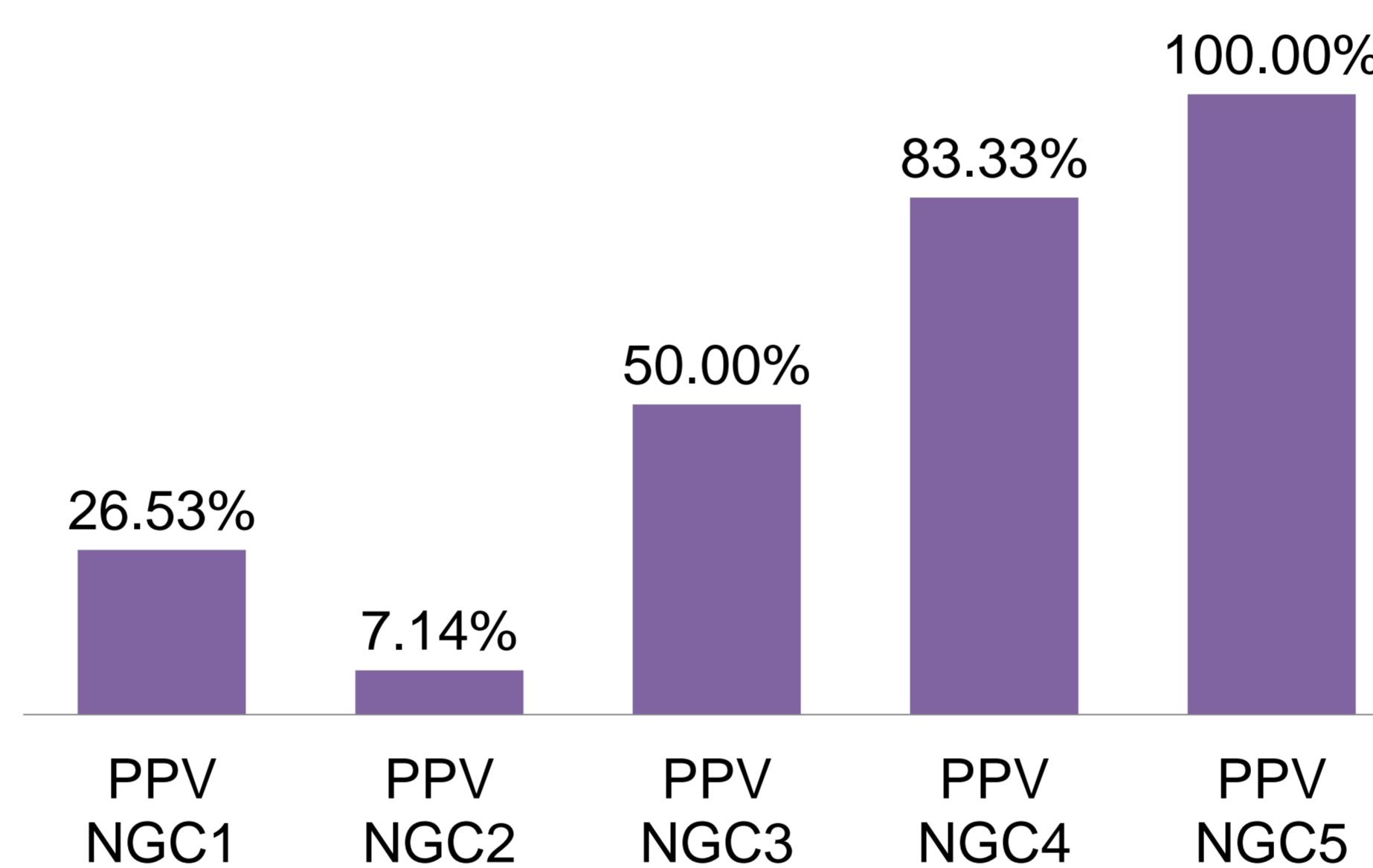
The spread of lump/lymph node cases from NGC1 to 5



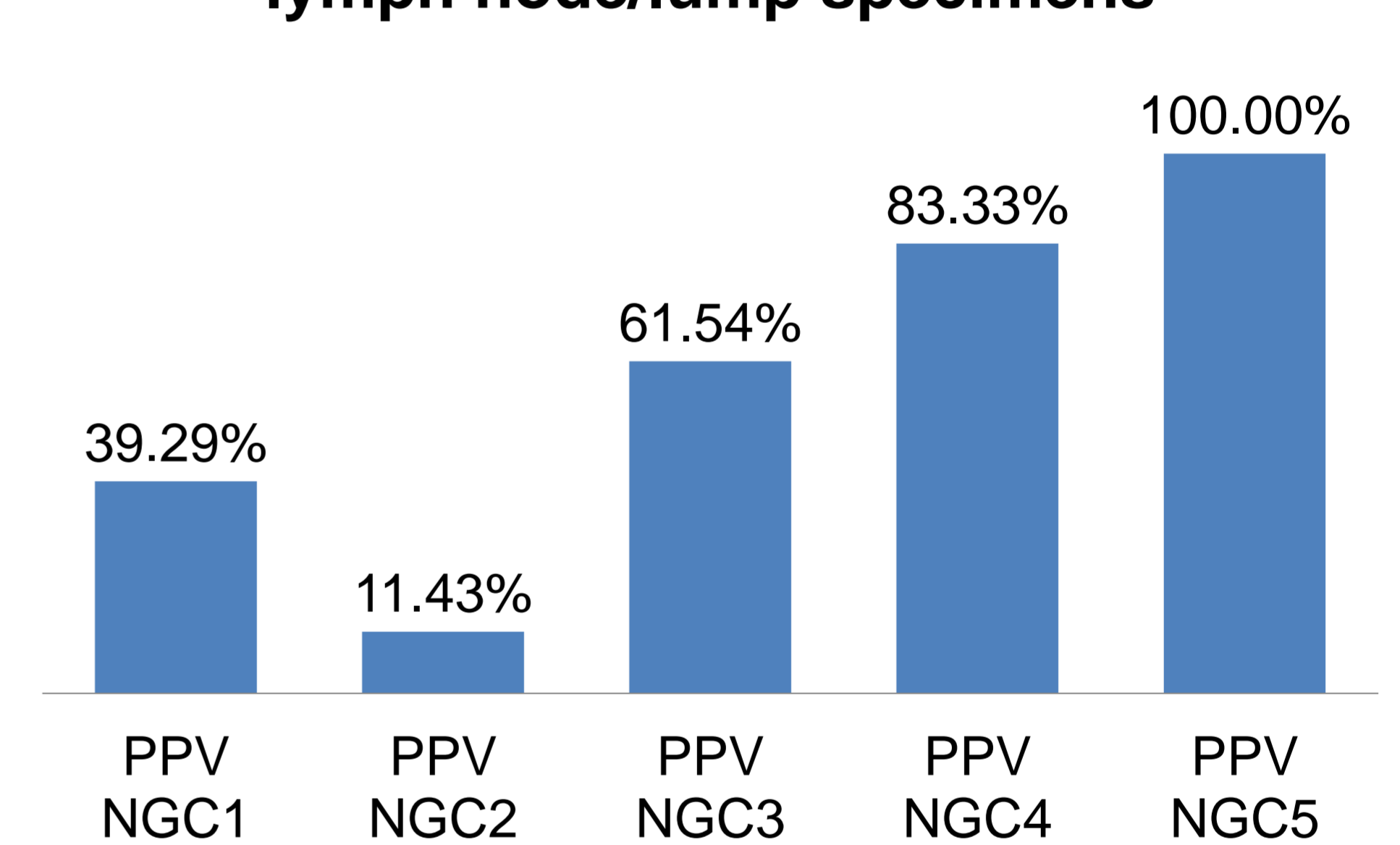
The spread of salivary gland cases from NGC1 to 5



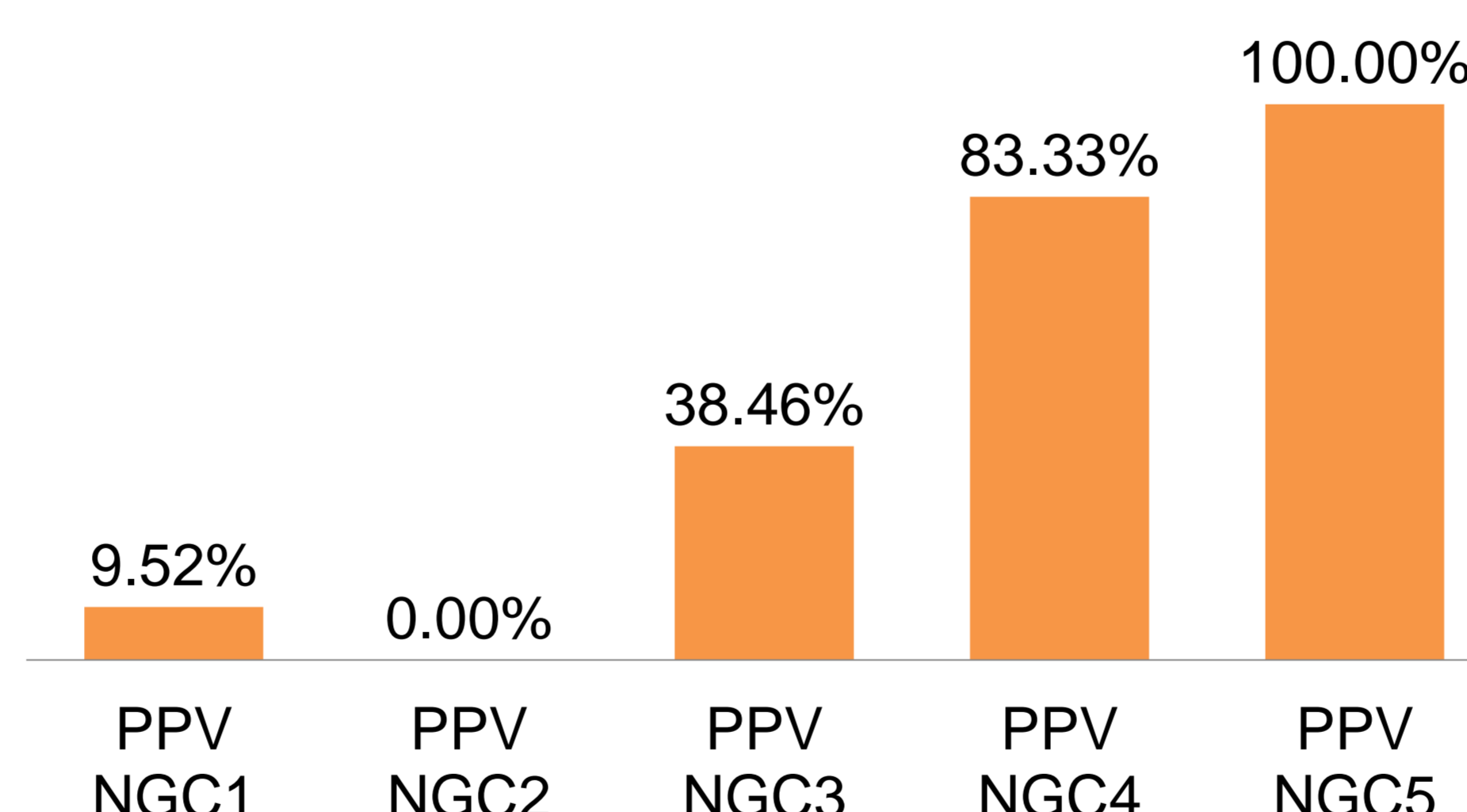
Overall PPV for each NGC category



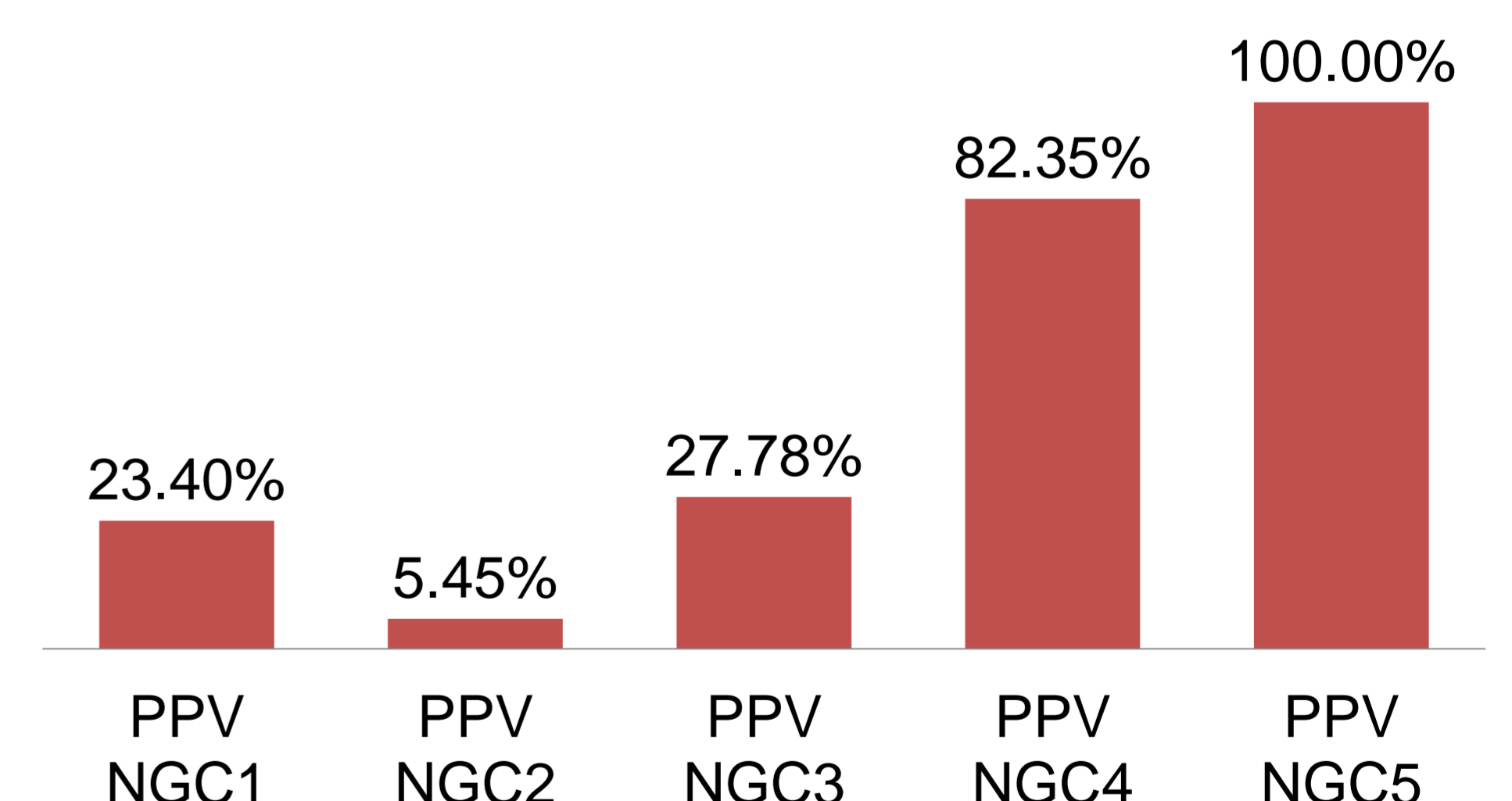
PPV for each NGC category in lymph node/lump specimens



PPV values for each NGC category in salivary gland specimens only



PPV value for diagnosis of carcinoma



Take-home message

- 100% PPV for malignancy if cytological features are malignant.
- False negatives were reviewed and found to often be lymphoma cases with 4 'true' false negatives.
 - These are a known difficult area in cytology and, with flow cytometry unavailable in our centre, an important source of type II error.
- Salivary gland cytology encompasses a variety of diagnoses and application of the Milan system in the future may help streamline the NGC3 and NGC4 categories.

1. Onur, I., Kulaçoğlu, S., Erucar, T. and Ergül, G., Fine needle aspiration cytology of head and neck masses: a cytohistopathological correlation study with emphasis on false positives and false negatives. *The Turkish Journal of Ear Nose and Throat*. 2013;23(3):163-172.
2. Kaye, P., Pigera, M., Khan, M., Hollows, P. and Beasley, N., Routine non-thyroid head and neck cytology in a large UK centre: clinical utility and pitfalls. *The Journal of Laryngology & Otology*. 2015;129(07):682-687.
3. Hafez, N., and Tahoun, N., Reliability of fine needle aspiration cytology (FNAC) as a diagnostic tool in cases of cervical lymphadenopathy. *J Egypt Natl Canc Inst* 2018; 23(3):105-14
4. Houcine, Y., Romdhane, E., Blel, A., Ksentini, M., Aloui, R., Lahiani, R., Znaidi, N., Ben Salah, M., and Rammeh, S., Evaluation of fine needle aspiration cytology in the diagnosis of cervical lymph node lymphomas. *J Craniomaxillofac Surg* 2018; 46(7):1117-1120
5. Rossi, E., Baloch, Z., Pusztaszeri, M. and Faquin, W., The Milan System for Reporting Salivary Gland Cytopathology (MSRSGC): an ASC-IAC-sponsored system for reporting salivary gland fine-needle aspiration. *Journal of the American Society of Cytopathology* 2018; 7(3), pp.111-118.